

JAPANESE SOCIETY OF HYPERBARIC AND UNDERSEA MEDICINE

THE 4TH CONFERENCE ON DIVING PHYSIOLOGY, TECHNOLOGY AND HYPERBARIC MEDICINE



Proceedings of The Conference in Tokyo

November 1~2, 2012

EDITED BY

Yoshihiro Mano, MD, Ph.D Japanese Society of Hyperbaric and Undersea Medicine

Treatment of Decompression Illness at Kawashima Orthopaedic Hospital

Kenji Miyata, Mahito Kawashima, Masayuki Kawashima, Hiroaki Tamura, Ikufumi Nagayoshi, Tatsuo Motoyama, Yukihiro Furue, Katsuhiro Takao & Takashi Yamaguchi

Kawashima Orthopaedic Hospital

INTRODUCTION

Most patients who were treated for decompression illness (DCI) at Kawashima Orthopaedic Hospital are professional diving fishermen from Kyushu. These fishermen tend to ignore decompression tables and dive based on their own experience to catch as many shellfish and fish as possible. Thus, they are prone to a high incidence of DCI. The purpose of this study is to investigate the effect of recompression treatment for DCI.

MATERIALS AND METHODS

The cases were 515 patients treated for DCI at Kawashima Orthopaedic Hospital from 1981 to 2011. They were from 17 to 76 years old, with an average age of 36.2. The purpose of diving was fishing in 435 cases (84.5%), construction in 27 cases (5.2%), and leisure in 22 cases (4.3%) and so on (Fig. 1). The pressurization methods were scuba in 405 cases (78.6%), hookah in 31 cases (6.0%), helmet in 24 cases (4.7%), caisson in 2 cases (0.4%), and skin diving in 1 case (0.2%) (Fig. 2).

DCI tended to occur more in less experienced divers than experienced divers (Fig. 3). The diving location was North Saga in 255 cases (49.5%), South Ooita and North Miyazaki in 117 cases (22.7%), and the Ariake Sea in 36 cases (7.0%) and so on (Fig. 4).

The maximum diving depth was less than 10m in 6 cases, 10-19m in 51 cases, 20-29m in 173 cases, 30-39m in 89 cases, 40-49m in 24 cases, and more than 49m in 25 cases. Many divers experienced DCI at more than 19 m (Fig. 5). The average diving depth was less than 10m in 12 cases, 10-19m in 110 cases, and 20-29m in 99 cases, indicating that most cases occurred at an average depth of 10-29m (Fig. 6).

Most DCI cases occurred within 1 hour of decompression and also many cases occurred during diving (Fig. 7).

DCI involved limb bends in 390 cases (75.7%), the spinal cord in 54 cases (10.5%), brain in 48 cases (9.3%), chokes in 10 cases (2.0%), and skin bends in 3 cases (0.6%) (Fig. 8).

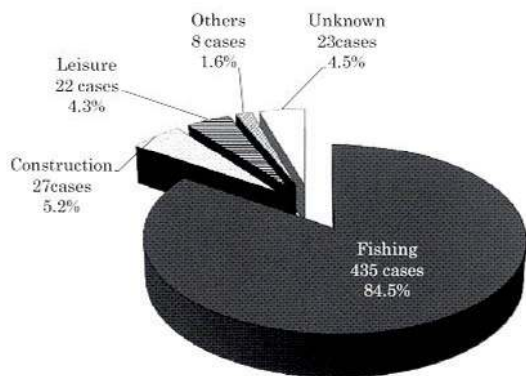


Fig. 1 Purpose of diving

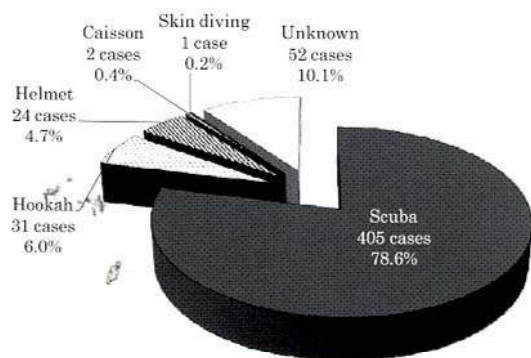


Fig. 2 Pressurization methods

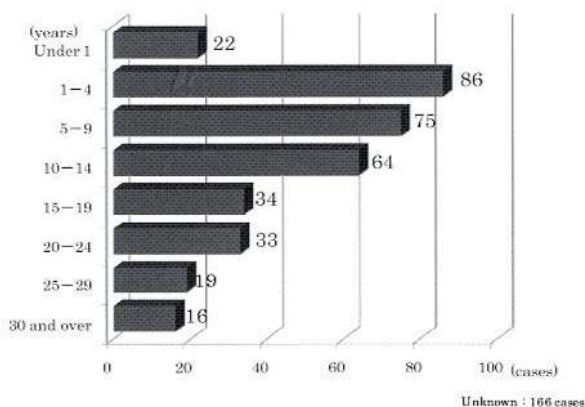


Fig. 3 Cases based on diving experience

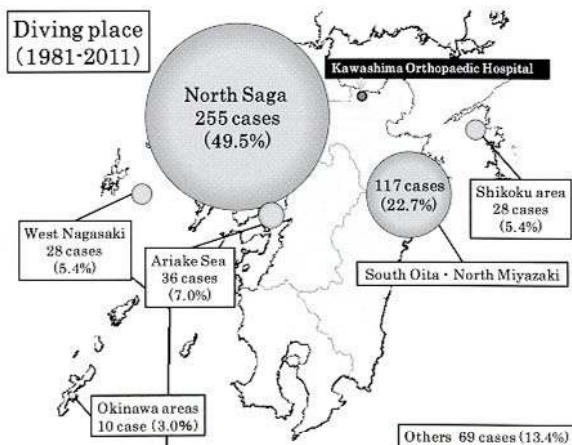


Fig. 4 Diving location

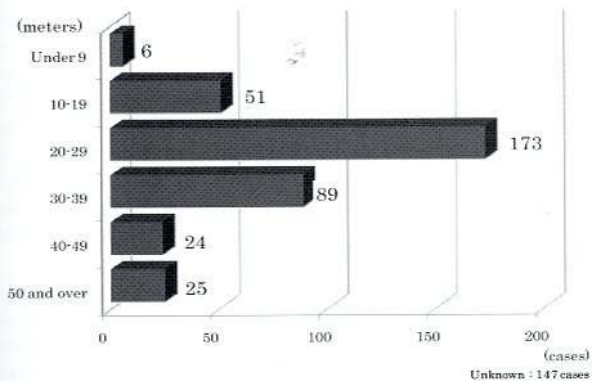


Fig. 5 Maximum depth

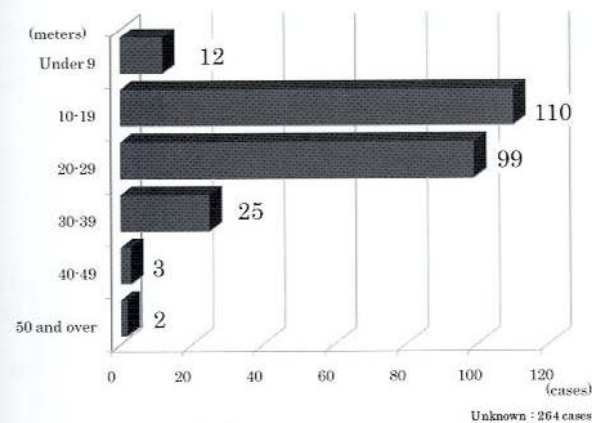


Fig. 6 Average depth

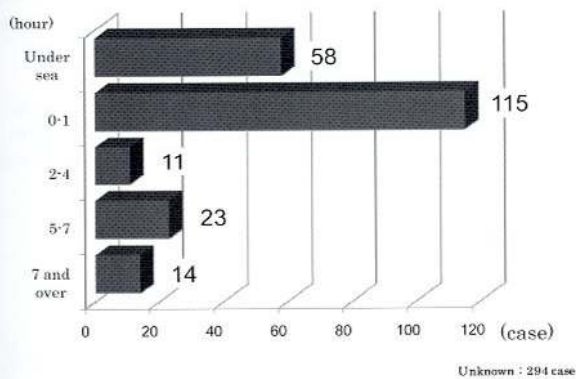


Fig. 7 Time of onset from decompression

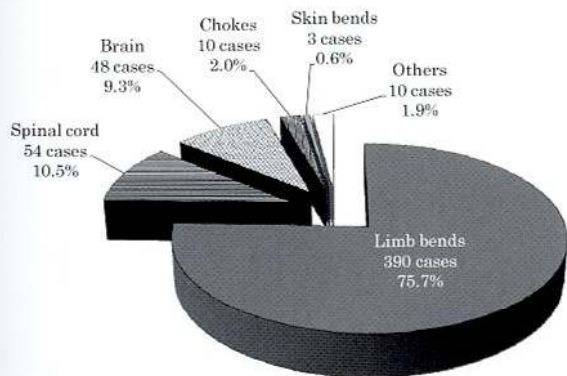


Fig. 8 Types of DCI

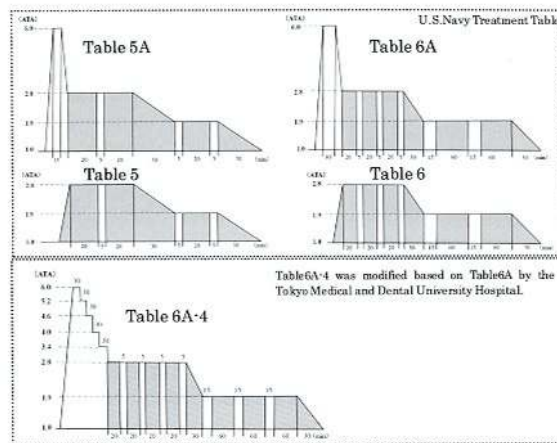


Fig. 9 Treatment tables for DCI

Case U-T
 Age 32 · Male
 Fisherman · Scuba
 DCI (Limb Bends on the right shoulder)
 Diving experience: 1 year
 Average depth: 20 m
 Maximum depth: 37 m

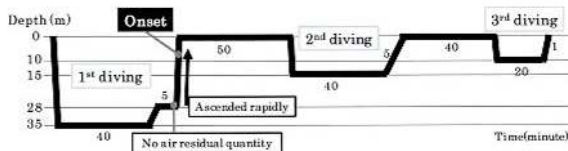


Fig. 10 Description of the case

Table 6A-4 is modified based on Table 6A by the Tokyo Medical and Dental University. We carried out Table 5A against type I DCI, and table 6A or table 6A-4 against type II DCI (Fig. 9). Commonly, we choose shorter time recompression table for the second treatment than the first one. Medication and/or rehabilitation are common therapy for DCI.

CASE

The patient was a 32-year-old fishing diver. He dived to 35m for 40 minutes and then ascended to 28m. After 5 minutes, he found his air tank nearly empty, and ascended rapidly to surface. During ascent, he felt pain on his right shoulder. However, he started diving again after a 50-minute-break. The pain increased after the third diving (Fig. 10). He did not come to our hospital immediately, but came the next day. Thus, the first recompression therapy was carried out 32 hours after onset, based on Table 5A. The pain almost disappeared during the first recompression. After recompression, the patient stayed in hospital and received anticoagulants and adrenocorticosteroids. The symptom disappeared completely the next morning and he was discharged.

RESULTS

“Good” outcomes here mean symptoms were eliminated, while “Fair” means symptoms clearly improved, and “Poor” means symptoms showed little improvement. Good outcomes were achieved for DCI with limb bends in 387 cases (99.2%), spinal cord in 41 cases (75.9%), brain in 37 cases (77.1%), chokes in 10 cases (100.0%), and skin bends in 1 case (33.3%) (Fig. 11). Among all 515 DCI cases, the outcomes were good in 484 (94.0%), fair in 29 (5.6%), and poor in 2 (0.4%) (Fig. 12)

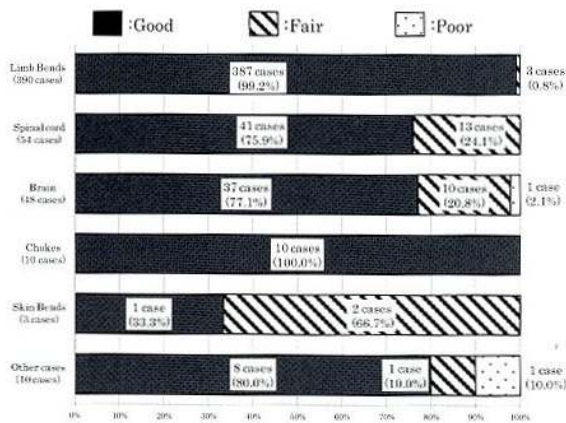


Fig. 11 Outcomes of types of DCI

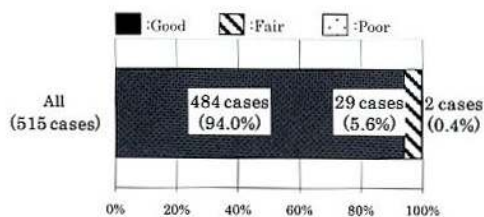


Fig. 12 Overall results

DISCUSSION

In 1878, Bert found that nitrogen gas dissolved in blood and interstitial fluid forms bubbles when a person rapidly decompresses after being in a high pressure environment for a certain time⁽¹⁾. DCI is caused by these bubbles under such conditions and prevention of DCI requires avoidance of rapid decompression based on specific criteria⁽²⁾. The U.S. Navy Diving Manual indicates that the onset time of DCI after completion of diving is within 1 hour in 42% of cases, within 3 hours in 60%, within 8 hours in 83%, and after 24 hours or more in 2%. The onset time was less than 5 hours in 83% of our cases.

DCI cases are classified into types I or II. Most type I cases involve limb joint pain and myalgia, and are referred to as limb bends. We carried out Table 5A against first treatment of type I DCI. However, Table 5A is not standard treatment in the guideline of U.S.Navy and the Japanese Society of Hyperbaric and Undersea Medicine (JSHUM). We conducted Table 5A for 390 cases, but there was no aggravated case. We conducted Table 5 on the next day, when a symptom did not disappear by first treatment. Most cases were improved by initial treatment. Therefore we are using Table 5A against type I DCI.

Type II DCI is classified as a pulmonary and central nervous system disorder. We carried out Table 6A against first treatment of type II DCI. Table 6A-4 was carried out for patients spinal cord paralysis above the 10th thoracic nerves⁽³⁾. We carried out Table 6 or 5 from the next day to about the 6th day.

Lactec (lactated Ringer's solution) was used for dehydration and steroids for spinal cord edema as adjuvant therapy, with a dose of 6000 U of heparin because DCI is associated with hypercoagulation. Symptoms remit with time in most type I DCI cases, but osteonecrosis may occur⁽²⁾. For this reason, it is important to carry out proper recompression treatment and fluid therapy as soon as possible.

CONCLUSION

- 1) 515 DCI cases were treated at Kawashima Orthopaedic Hospital from 1981 to 2011.
- 2) DCI involved limb bends in 390 cases (75.7%), spinal cord in 54 cases (10.5%), brain in 48 cases (9.3%), and chokes in 10 cases (2.0%).
- 3) The outcomes of DCI were good in 484 cases (94.0%), fair in 29 cases (5.6%), and poor in 2 cases (0.4%).

REFERENCES

- 1) Paul Bert: Barometric Pressure (1878), Translated from the French by Mary Alice Hitchcock, M.A., Originally Published by College Book Company Columbus, Ohio, Maryland, Impressions Ltd, 1943
- 2) Mahito Kawashima et al: The recent tendency of dysbaric osteonecrosis in Japanese divers, JSHUM 41: 73-76, 2006
- 3) Mahito Kawashima et al: The Treatment of Decompression Sickness, JSHUM 35: 177-182, 2006

Treatments of Dysbaric Osteonecrosis

Masayuki Kawashima, Mahito Kawashima, Hiroaki Tamura, Ikufumi Nagayoshi, Katsuhiro Takao, Takashi Yamaguchi, Kenji Miyata

Kawashima Orthopaedic Hospital

It is well known that inappropriate or excessive diving causes dysbaric osteonecrosis (DON). DON is frequently found in upper humerus and upper femur among divers and caisson workers. Half of the cases of DON are seen in the proximal femur¹⁾ (Fig.1). We found one third of divers without symptom had DON in the physical examination, and half of the divers with DON had multiple lesions¹⁾ (Fig.2). We also found that the divers who work for less than 10 hours a week didn't have DON¹⁾ (Fig.3). DON of upper femur causes the collapse of the femoral head, and develops into osteoarthritis (OA) of the hip joint with

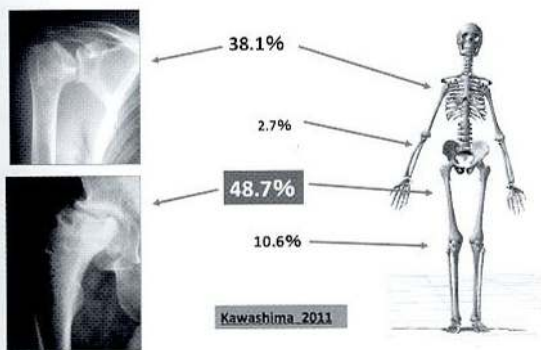


Fig. 1 Dysbaric Osteonecrosis

| Number of Lesion of DON | | |
|-------------------------|-------------|-------|
| DON | 56/154cases | 36.4% |
| Number of lesion | Cases | Rate |
| 1 | 30 | 54% |
| 2 | 10 | 18% |
| 3 | 7 | 13% |
| 4 | 6 | 11% |
| 5 | 2 | 4% |
| 6 | 1 | 2% |
| Total | 56 | 100% |

Fig. 2 Prevalence of DON at Physical Examination

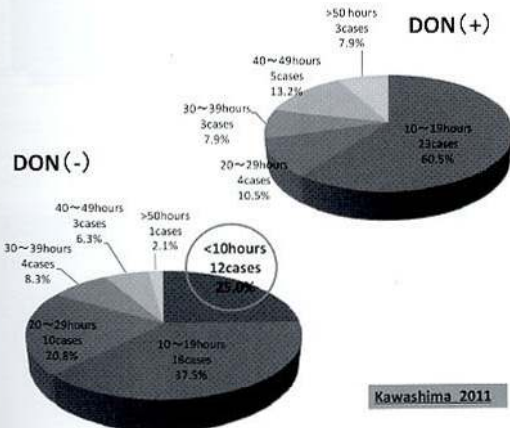


Fig. 3 Diving Hours a Week

pain and restriction of activity in daily life. If once collapse takes place, progression of destruction is usually relentless, and surgical methods are indispensable.

There are several operations for the avascular necrosis of the femoral head. In our series, operations for DON of the femoral head are divided into three groups; varus trochanteric osteotomy, transtrochanteric anterior rotational osteotomy, and prosthetic femoral head replacement arthroplasty.

(1) Varus Trochanteric Osteotomy

Distal osteotomy is cut transversely across shaft at just above level of lesser trochanter and the small wedge of bone based medially is excised. A corrected angle is often the range from 15 to 20 degrees. Angle blade plate is used to fix between osteotomy fragments. Healthy bone is brought into the weight-bearing area.

(2) Transtrochanteric Anterior Rotational Osteotomy (ARO)

In 1978, Sugioka described a transtrochanteric rotational osteotomy of the femoral head²⁾. The femoral head is rotated anteriorly between 45 to 90 degrees, depending on size of the necrotic area that must be rotated away from the weight-bearing position. Even in many advanced cases of DON, the posterior part of the femoral head often retains a normal, smooth contour containing healthy cartilage. Large screws are used to fix internally between osteotomy fragments.

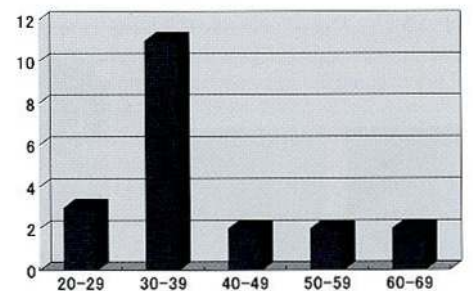
(3) prosthetic femoral head replacement

This method is chosen for reconstruction of the hip joint with extensive DON or OA.

Recently, hip resurfacing has been introduced as an alternative to standard total hip arthroplasty (THA), especially for young and active patients. Possible advantages include greater hip joint stability, bone preservation, and decreased osteolysis.

Surgical treatment for DON of the femoral head was done to 19 patients with 20 hips from 1981 to 2012 at Kawashima Orthopaedic Hospital. They were all male. 13 patients of 19 were professional diving fishermen, 3 were commercial divers, and the others were caisson workers. Their ages at the operation ranged from 24 to 61 years old. The average age was 39.0 years old (Fig4).

In our series, varus osteotomy was done to 5 patients, transtrochanteric anterior rotational osteotomy was 12 and



Age at the first operation 24~61
Average age 39.0

Fig. 4 Age Levels at the Surgery

prosthetic femoral head replacement arthroplasty was 3. A follow-up found satisfactory results in 13 patients. 5 patients who had varus trochanteric osteotomy had good results. 3 of 12 patients who had transtrochanteric anterior rotational osteotomy had severe progression of collapse in newly created weight-bearing area, and one had delayed union and dislocation after surgery. One of those was done cup arthroplasty of the femoral head at 29 months later from the initial operation. As for one of three patients who had prosthetic femoral head replacement, re-operation was required several times.

Case Reports

Case 1.

A 27 year-old diving fisherman (Fig.5). The preoperative radiograph showed DON at the right femoral head. Transtrochanteric anterior rotational osteotomy was done. After 90° of anterior rotation, healthy posterior cartilage was transported to weight-bearing area. There is no evidence that the newly created weight-bearing area has collapsed 11 years after surgery.

Case 2.

A 36 year-old diving fisherman (Fig.6). The preoperative radiograph and MRI showed DON at the left femoral head. The characteristic of his diving profiles was long exposure in the bottom of the sea and short decompression time from the bottom to surface. Varus trochanteric osteotomy was done because lateral part of the femoral head was the uninvolved portion. The newly created weight-bearing area is kept well for 5 years and 2 months after surgery and he feels no pain. The MRI findings seem to show the repair of the necrotic area.

Case 3.

A 62 year-old diving fisherman (Fig.7). He had 44 years diving experience. His average depth of diving was 10 m and maximum depth was 30 m. He started to feel pain with the right hip joint 11 years before the surgery. He had continuous pain of the right hip joint and limp severely just before the surgery. The preoperative radiograph showed DON and destruction at the right femoral head. MRI and CT showed extensive DON and the structural subchondral collapse. Prosthetic femoral head replacement was done and his pain disappeared completely.

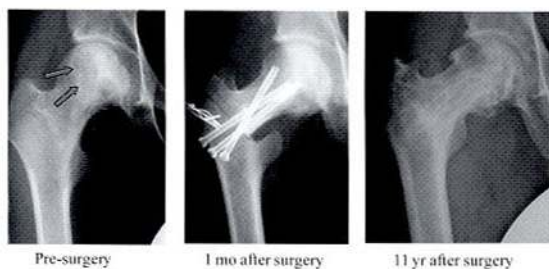


Fig. 5 Case 1. O.K Age 28

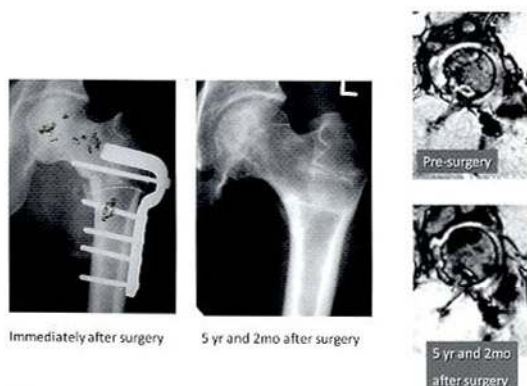

Fig. 6 Case 2. H.T Age 35

Case 4.

A 58 year-old man (Fig.8). He is a commercial diver using aqualung diving for many years. After he fell down with a 40kg stone on the ground, he began complaining of right hip pain and limping. Because he could not continue his work due to the pain, he was admitted to our hospital for surgical treatment. The preoperative radiograph and MRI showed DON at the right femoral head. Metal on metal hip resurfacing was done and his pain effectively disappeared. He hasn't felt hip pain for 4 years and kept his activity.

Discussion

If nonsurgical treatment for DON of the femoral head is prolonged, the optimal time for proper operation may be missed and the collapse of the femoral head and osteoarthritis of the hip joint will develop. Osteotomy with the transposition of the weight-bearing portion is often chosen for the patients of DON of the femoral head, because many of these patients are young. After the varus trochanteric osteotomy or ARO, the necrotic area is moved so that maximal stress is expected to fall on the uninvolved surface of the femoral head. Varus osteotomy is indicated in the cases where lateral part of the femoral head doesn't have ischemic process. In our series, results were very good because necrotic area of the femoral head was not so extensive in these cases.

ARO was introduced for idiopathic avascular necrosis to prevent progressive collapse of the articular surface by Sugioka. Its procedure is technically demanding. The posterior branch of the medial femoral circumflex artery, which supplies the blood flow to femoral head, must be protected carefully during this surgery. ARO is very effective operation, because the range of necrosis is often extensive in the patients of DON of the femoral head.

In our series, progressive collapse in newly created weight-bearing area occurred in 3 hips in 12 osteotomies. Main courses of this change are that the lesions had been more extensive and collapse had already occurred at the initial surgery. Postoperative degenerative changes can be anticipated when these osteotomies are performed in patients with advanced necrosis.

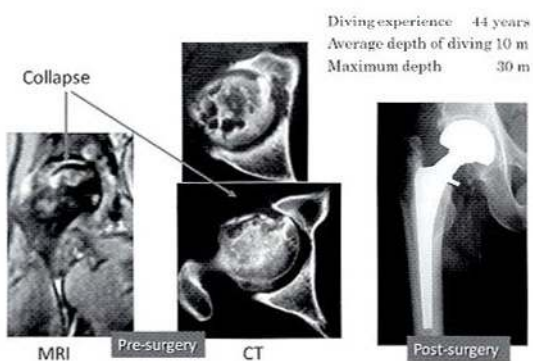


Fig. 7 Case 3. K.T Age 61

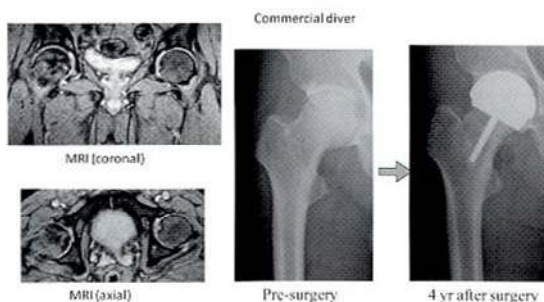


Fig. 8 Case 4. Y.T Age 58

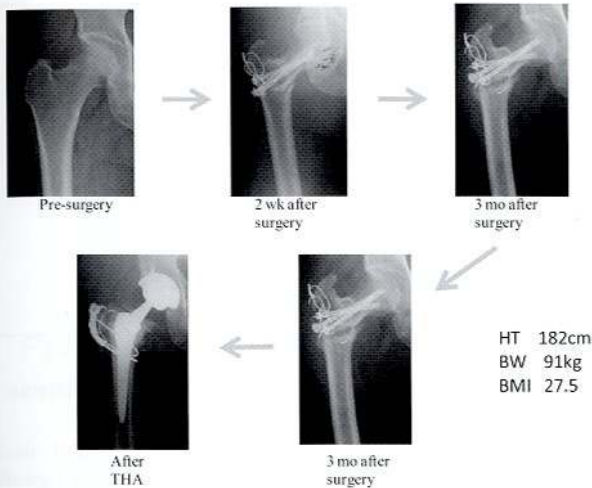
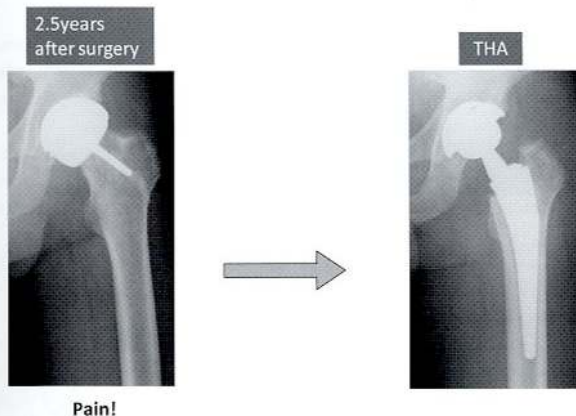


Fig. 9 Non-Union after ARO



But abnormality was not found in the X-ray.

Fig. 10 Hip Resurfacing

Patient may fail to bone union because of pseudarthrosis (Fig.9). We should better avoid ARO for patient with heavy body weight. It is difficult to decide which procedure we should choose in these cases.

Prosthetic replacement is not indicated as the initial surgical treatment in the young and early middle-aged patients. Patient treated with osteotomy needs long hospital stay, however, the patient is forced to shorten the length of hospital stay in Japan for medical cost containment policy recently. The patients undergone hip resurfacing are permitted postoperative weight bearing earlier than osteotomy, and they are able to come back to daily life soon³⁾⁻⁵⁾. Hip resurfacing is remarkable because of the potential benefits of femoral bone conservation, greater hip joint stability, possible decreased osteolysis, and increased functional ability compared with standard THA. Hip resurfacing, especially modern metal-on-metal total hip resurfacing have possibility to be an alternative procedure for young patients. However, we experienced the case that the pain didn't disappear. Hip resurfacing may not suit DON of the femoral head with extensive necrotic area (Fig.10).

The surgical procedure of hip resurfacing is more difficult than THA. Recently, the device of THA develops year by year, and survival rate has improved. Hip microplasty is given to a design of hip replacement that has a particularly short stem to its femoral component (Fig.11). The object is to preserve as much of the femur bone as possible at surgery, as this allows the possibility of a more traditional hip replacement in the years to come. There is a possibility that prosthetic replacement will be adapted to the younger people instead of osteotomy.

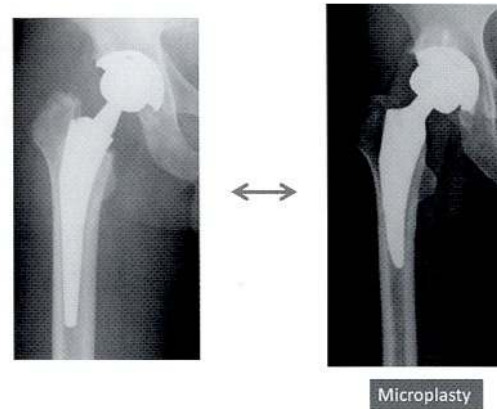

Fig. 11 Development of Prosthetic Replacement

| DON | (+) 25 cases | (-) 67 cases |
|--------------|-------------------|-------------------|
| bends (*1) | 13 (52.0%) | 20 (29.9%) |
| spine | 1 (4.0%) | 1 (1.5%) |
| brain | 2 (8.0%) | 4 (6.0%) |
| squeeze | 2 (8.0%) | 2 (3.0%) |
| unknown | 0 (0.0%) | 1 (1.5%) |
| Total | 17 (68.0%) | 25 (37.3%) |

(*1) χ^2 examination $p < 0.05$

Kawashima 2011

Fig. 12 Past History of Decompression Sickness

In the group of men with one or more bone lesion, 52.0 % were known to have previous bends experience¹⁾ (Fig.12). Hard work and inadequate decompression seem to result in development of bone lesion among Japanese diving fishermen. Prevention of bends is one of the important elements to prevent DON. Short exposure at the bottom and slow decompression using a universal table might prevent development or decrease the prevalence of DON.

References

- 1) Kawashima M, Kawashima M, Tamura H, et.al. Dysbaric Osteonecrosis Nihon Kokiatsu Kankyo Sensui Igakukai Zasshi. 2011; 46:268
- 2) Sugioaka Y. Transtrochanteric anterior rotational osteotomy of the femoral head in the treatment of osteonecrosis affecting the hip-a new osteotomy. Clin.Orthop. 1978; 130: 191-201
- 3) Mont MA, Seyler TM, Marker DR, et.al. Use of metal-on-metal hip resurfacing for the treatment of osteonecrosis of the femoral head. J Bone Joint Surg Am. 2006; 88: 90-97
- 4) Revell MP, McBryde CW, Bhatnagar S, et.al. Metal-on-metal hip resurfacing in osteonecrosis of the femoral head. J Bone Joint Surg Am. 2006; 88:98-103
- 5) Amstutz HC, Le Duff MJ, Campbell PA, et.al. The effect of technique changes on aseptic loosening of the femoral component in hip resurfacing. Results of 600 conserve plus with a 3 to 9 year follow-up. J Arthroplasty. 2007; 22: 481-489
- 6) Kawashima M, Nagayoshi I, Tamura H, et.al. Hip Resurfacing for Dysbaric Osteonecrosis. The 3rd Conference U.S.-Japan Panel on Aerospace, Diving Physiology & Technology and Hyperbaric Medicine (Proceeding). 2008; 136-140

Pathophysiology of Dysbaric Osteonecrosis

Mahito Kawashima¹⁾, Masayuki Kawashima¹⁾, Hiroaki Tamura¹⁾, Ikufumi Nagayoshi¹⁾, Tatsuo Motoyama¹⁾,
Yukihiro Furue¹⁾, Katsuhiko Takao¹⁾, Kimihiro Yoshida¹⁾, Takashi Yamaguchi¹⁾, Kenji Miyata¹⁾,
Yoshihiro Mano²⁾, Motoo Kitano³⁾

¹⁾Kawashima Orthopaedic Hospital

²⁾Tokyo Medical & Dental University

³⁾Kagoshima University

Fish diving in Japan

In Japan, traditional breath-hold diving called "Ama" has been around from long time ago. They dive to catch shellfish and fish. Most of them are women. Their diving style is unique: they dive wearing only goggles and simple clothes. In several areas in Japan which have plenty of shellfish, we see them a lot. However, it seems that the number of traditional "Ama" diving is decreasing in recent years. In fish diving with diving equipment, divers use scuba, helmet or hooka. These days, most fish divers use scuba equipment.

Investigation of Dysbaric Osteonecrosis in Oura

In Oura village which faces the Ariake-sea in Kyushu, helmet diving is traditional to catch pen shell/Tairagi shellfish (*Atrina-japonica*). When I worked at Kyushu Rosai Hospital, I learned the fact of high incidence of dysbaric osteonecrosis (DON) among fish divers from one of my colleagues' research. In those days, my mentor, Dr. Tamikazu Amako requested I research hyperbaric medicine and DON. Thus I started investigating DON in Oura in 1973 (Fig.1).

We put a diving recorder to divers to record their diving patterns. What's unique about their diving is that they dive for a long time such as for 3 to 8 hours at 10 to 40 meters depth at one diving, once a day. We could assume they dive in such a reckless way because even if they worked hard, the profit was small. So, they had to work harder to catch more shellfish for their life.

We then x-rayed their shoulders, femurs and hip joints, noticing high incidence of DON 59.6% (268 out of 450 divers)^{1,2)} (Fig.2).

We looked at the relationship between the occurrence of DON and their experience of the bends. There were 196 bends cases in 268 DON cases (73.1%). It shows that the experience of bends is related to the occurrence of DON by the chi-square test ($p < 0.01$)³⁾.

Even, after I started my own practice, I continued medical check-ups of divers. DON was found 442 cases out of 952 divers (46.4%) between 1972 and 2003.



Fig.1 Fishing diver & investigation of DON in Oura

Four autopsy cases of decompression illness

We conducted an autopsy on 4 divers who died from decompression illness and studied their femur head pathologically.

Case 1 showed the most acute clinical course, with fatal chokes. Multiple air bubbles were found in the femoral sinusoids. A characteristic finding was platelet aggregation in the vicinity of the femoral bubbles (Fig.3, 4).

Case 2 was also acute with chokes and spinal cord paralysis. Fat emboli were recognized in the lung vessel. Air bubbles, platelet aggregation, and an accumulation of fat were recognized in the dilated sinusoids (Fig.5, 6).

Case 3 died 5 days after the onset of spinal cord paralysis. An extensive necrosis was noted around the dilated sinusoids. Platelets aggregation and thrombosis were seen in the sinusoids (Fig.7).

Case 4 died 14 days after the onset of spinal cord paralysis. Slight hemorrhage, migration of phagocytes, and fibrosis were found around the femoral sinusoids.

In case 1 and 2, which had the most acute clinical course, there was platelet aggregation adjacent to the vacuoles, slight to moderate bleeding with congestion of bone marrow, and sludging of red blood cell in the dilated venules which had close relation to vacuoles.

In case 3 and 4 which were died 5 and 14 days each after onset decompression illness, there was rather extensive necrosis accompanied by hemorrhage and edema occurred in the bone marrow tissues surrounding the vacuoles. Some sinusoids dilated by expanding air bubbles were seen. There was platelet aggregation or platelet thrombi in the arterioles and sinusoids. From these appearances, bubble formation and platelet aggregation seemed to have significance in the pathogenesis of acute decompression sickness and osteonecrosis in diver^{4,5)}.

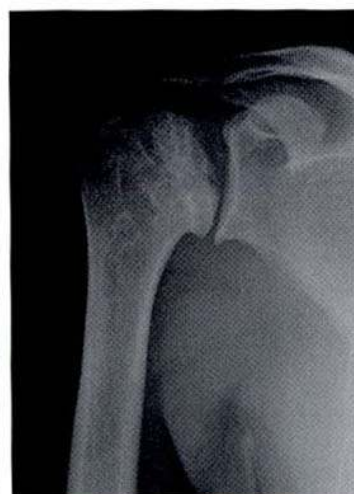

Fig.2 Type A5 DON on the X-ray

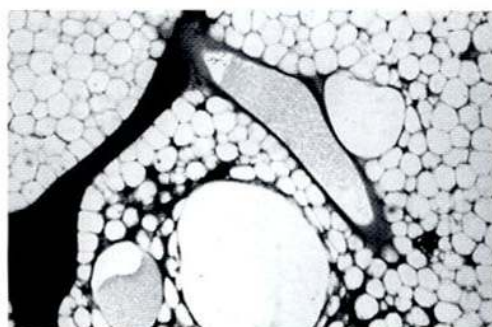


Fig.3 Case1 Dilated sinusoid and platelets aggregation of the femoral head

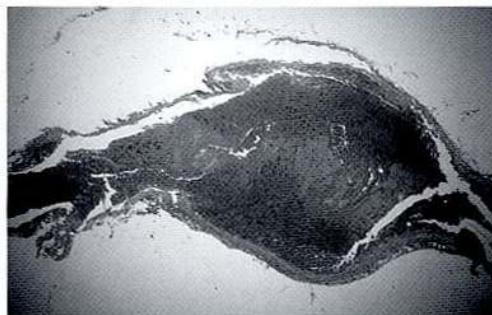


Fig.4 Case1 Venous thrombosis in the epidural vein

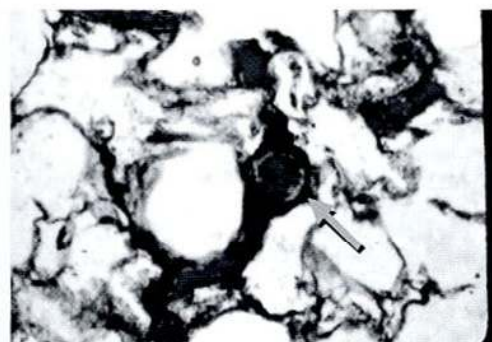

Fig.5 Case2 Fat emboli in the lung

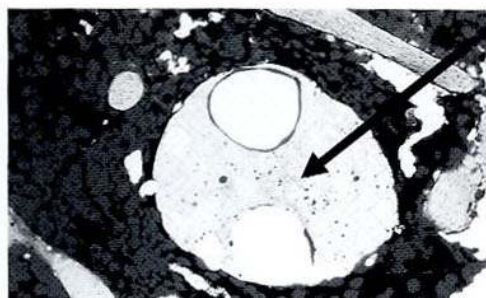


Fig.6 Case2, Dilated Sinusoid of the femoral head, accumulation of fat, and aggregation of platelets in the vicinity of air bubbles

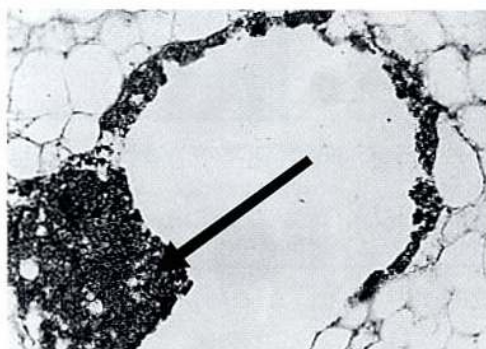


Fig.7 Case3, Platelet Thrombosis was seen in the bone marrow of the femoral heads

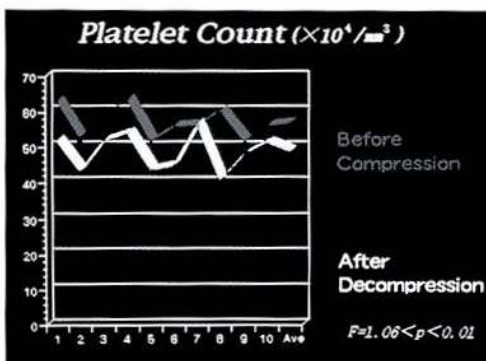


Fig.8 The number of platelets before and after the experimental of compression-decompression in rat

Hematological examination of decompression illness in rats and rabbits

We did hematological examination of decompression illness using rats and rabbits. We made each animal decompression illness condition by pressurizing to 6ATA and decompressing quickly. We checked their blood before and after the procedure.

Before the procedures, the number of circulating platelets of the rats was ranging from 515,000/mm³ to 634,000/mm³ and the average was 597,000/mm³. Most of the animals showed more or less decrease in the numbers of platelets after the procedures and it was ranging from 408,000/mm³ to 566,000/mm³ (average was 491,300/mm³). The difference of the numbers of circulating platelets was highly significant ($p < 0.01$)⁽⁶⁾ (Fig.8).

The thrombelastograph of one of the rabbits showed shortening of *k* and *r* widening of *ma*. After the compression-decompression procedure, in comparison with the thrombelastograph taken before the procedure. Histopathologically, we found that there were numerous large or small air bubbles up to 2,000 microns in diameter in the sinusoids

of the bone marrows of femurs in the all subjects. Platelet aggregation was noted in the vicinity of some bubbles. The thrombus formation was marked around the bubbles in the other areas. Accumulation of fibrinogen substance was demonstrated by application of FITC-conjugated anti-rabbit-fibrinogen sheep-IgG on femoral bone marrow around the bubbles in the sinusoids. Numerous air bubbles were seen in the blood of the vena cava and the right atrium and ventricle of the heart and of the pulmonary arteries. Accumulation of fibrin clots was confirmed in the vicinity of the intravascular air bubbles and also in the small vessels of the lung by fluorescent microscopy⁽⁶⁾.

Experimental dysbaric osteonecrosis in sheep, cooperative research with Wisconsin University

We sent recorded Oura diving profiles to Dr. Charles Lehner, a cooperative researcher for DON in the University of Wisconsin-Madison. They simulated the same diving based on the recorded profiles on sheep in a hyperbaric chamber⁽⁷⁾.

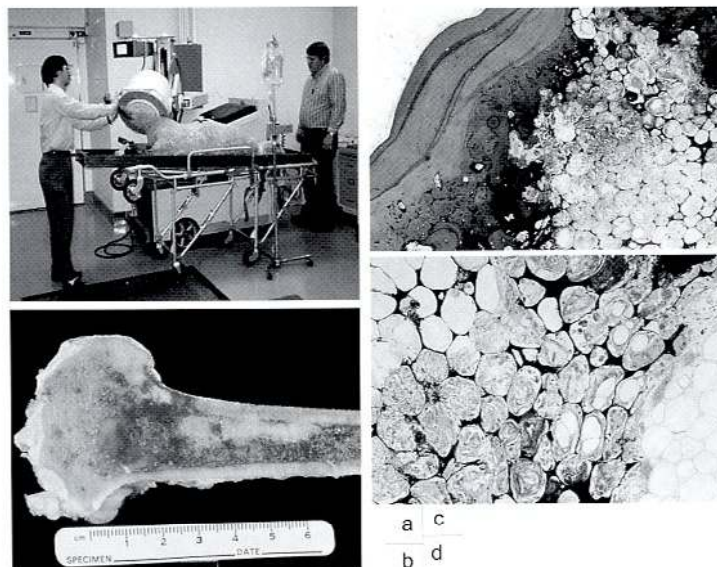


Fig.9-a) Experimental DOS of Wisconsin in Sheep, b) DON on long bone of sheep, c)d) DON of sheep femur

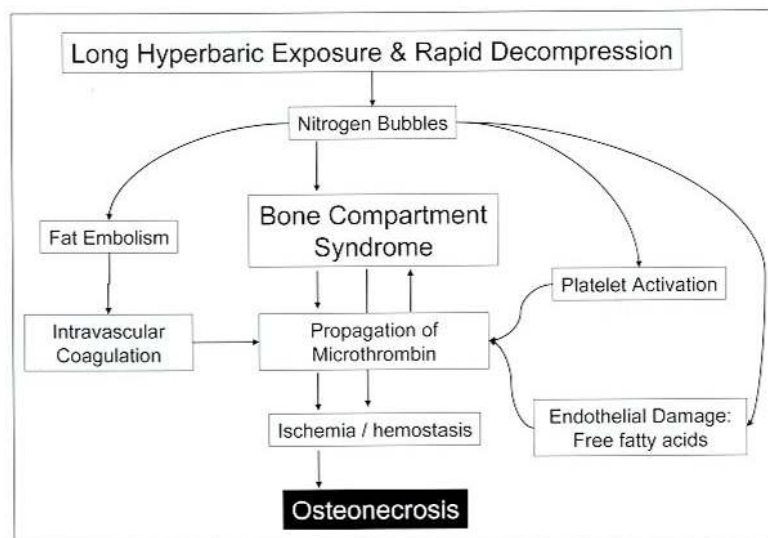


Fig.10 Pathogenesis of DON

They succeeded in making experimental bends and DON in the sheep long bone. Macroscopically, we found that fatty marrow necrosis which is common in DON was seen in the sectioned bone specimens of sheep femora. Fatty marrow necrosis appeared as opaque, yellow-white inclusions in the marrow cavity. Histological findings are focal liquefaction of in the necrotic lesion. Endosteal new bone formation was present in the cortical bone. Necrotic fatty marrow is surrounded by a fibro osseous layer. Individual necrotic fat cells were enveloped by basophilic material of calcified tissue. Articular cartilage appeared intact. The histological findings were also essentially identical to those found in Japanese diver's DON which was reported by us. However in divers, the prevalence of necrotic foci appeared to be almost as high in the femoral as in the distal femoral shafts (Fig.9).

Pathophysiology of DON

From these examinations and medical check-ups, we assume the onset factors of DON as follows:

- 1) Long exposure to high pressure
- 2) Presence of a lot of adipocyte
- 3) Rapid decompressing

These conditions could cause DON. In other words, nitrogen dissolves much more in adipocyte, and the blood flow is slower

around the adipocyte. The bone marrow cavity is semi-closed space. Therefore, bubbles were generated due to inappropriate decompression. After that the tissue pressure rose, and bone compartment syndrome was induced. As a result, blood flow and nitrogen discharge stopped.

The other important thing is intravascular obstruction. Nitrogen bubbles in the vascular cause blood coagulation. Nitrogen bubbles explode adipocyte, and discharge adipocyte into bone marrow cavity. As a result, bone marrow vascular was obstructed (Fig.10)^{8,9}.

The number of incident of DON

We have done medical check-ups of divers since 1972. The number of them has decreased compared to when I worked at Kyushu Rosai Hospital. We checked 747 divers between 1972 and 1980 while there were only 205 divers between 1981 and 2003. The incident rate has also decreased. It was 59.2% from 1972 to 1981 while it was only 10.2% from 1981 to 2003 (Fig.11). We assume that they work shorter as they started to learn the risk of the DON. Another reason is there is much less pen shell around there due to environmental change.

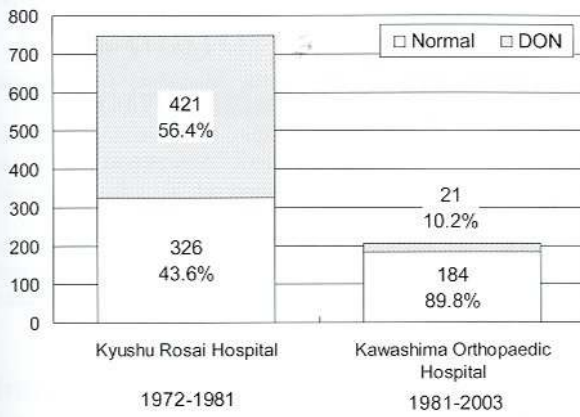


Fig. 11 The number and incident rate of DON

Prevention of DON

Vitamin E is known as having platelet aggregation inhibition effect. We studied the number of platelets in Vitamin E-deficient group, control group and vitamin E diets group after decompression using rats. There was a significant fall of the number of platelets immediately after decompression in vitamin E-deficient diets rats and control rats. However, there was no significant fall of platelet count in vitamin E diets rats. The result suggested that vitamin E reduce platelet loss and prevented the post decompression increase in platelet adhesiveness. Vitamin E inhibits platelet adhesiveness and aggregation after decompression (Table 1, 2, 3, 4)¹⁰.

Recently, there are some reports about prevention of osteonecrosis. Kuribayashi reports that the incident rate of osteonecrosis was lower to the rat which gave vitamin E enough than not gave it enough¹¹. Ishida reports that occurrence of osteonecrosis was inhibited by the electric stimulation in rabbit¹². Nishi reports the incident rate of steroid-induce osteonecrosis is low in subjects given biphosphate¹³.

It is important to follow the standard table to avoid decompression illness. If symptom of decompression illness appeared, you should receive the recompression treatment and anticoagulant soon. Additionally, DON may appear to divers who have long experience of diving without decompression illness. Divers should receive a medical check-up regularly.

Conclusions

1. We have investigated DON of diving fishermen since 1973 in Japan.
2. We found 442 cases of DON out of 952 divers.
3. DON is induced by inappropriate high pressure exposure and decompression.
4. Decompression may form bubbles in the semi-closed compartment of the long bone. If significant numbers of bubble form, tissue pressure can rise and ischemia may occur. Persistent limb bends may reflect elevated bone marrow pressure and ischemia in the long bones. If the ischemia is sustained, then dysbaric osteonecrosis may occur.
5. Persistent ischemia may occur by the proposed mechanism of a bone compartment syndrome in the development of DON.
6. A bone compartment syndrome may be promoted by intraosseous hypercoagulation and fat embolism. These factors appear to be the pathogenetic mechanism, which is most likely to be responsible for DON.
7. Vitamin E may prevent occurrence of DON.
8. Early recompression therapy with anticoagulant therapy may prevent the development of DON.

Table 1 Effects of Decompression on platelets in control rats.

| Count before Compression | Count after Decompression |
|--|--|
| 56.13 ± 4.14 | 39.06 ± 12.98 |
| (× 10 ⁴ /mm ³) | (× 10 ⁴ /mm ³) |

Table 2 Serum Vitamin E in rats

| | Received Vitamin E | No. of Rats | Serum Vitamin E |
|----------------|--------------------|-------------|-----------------|
| A E-Deficient | 5 mg/kg | 12 | 0.31 mg/dl |
| | | | 0.15 mg/dl |
| B Control | 20 mg/kg | 12 | 0.42 mg/dl |
| | | | 0.52 mg/dl |
| C E-Sufficient | 200 mg/kg | 12 | 0.85 mg/dl |
| | | | 1.22 mg/dl |

Table 3 Effects of decompression on platelets in rats

| | Count before Compression (× 10 ⁴ /mm ³) | Count after Decompression (× 10 ⁴ /mm ³) |
|----------------|---|--|
| A E-Deficient | 64.84 ± 3.70 | 56.66 ± 5.03 |
| B Control | 56.28 ± 3.12 | 45.62 ± 13.84 |
| C E-Sufficient | 48.26 ± 7.23 | 50.94 ± 7.78 |

Table 4 Survival rate after decompression

| | Survival | Death | Total |
|----------------|-----------|------------|-------------|
| A E-Deficient | 2 (16.7%) | 10 (83.3%) | 12 (100.0%) |
| B Control | 3 (25.0%) | 9 (75.0%) | 12 (100.0%) |
| C E-Sufficient | 6 (50.0%) | 6 (50.0%) | 12 (100.0%) |

References

- 1) Hayashi, K., Kawashima, M., Torisu, T., and Kamo, H, Decompression sickness and the changing of bone and joint, *Rinshou Seikei Geka* 9.1(1974).10-18(Japanese).
- 2) Kawashima, M, Aseptic bone necrosis in Japanese divers. *The bulletin of Tokyo medical and dental university* 23.2(1976).71-92
- 3) Kawashima, M, Torisu, T, Kamo, H and Hayashi, K, Decompression sickness and the changing of bone and joint 3. *The dysbaric osteonecrosis of divers and diving condition*, *Rinshou Seikei Geka* 9.3(1974).18-28(Japanese).
- 4) Kawashima, M., Hayashi, K., Torisu, T., and Kitano, M., *Histopathology of the early stage of osteonecrosis in dives*. Reprinted from the *Undersea Biomedical Research Journal* 4.4(1977).409-417
- 5) Kawashima, M, Torisu, T, Hayashi, K, *Pathological review of osteonecrosis in divers*. *Clinical orthopaedics and related research* 130(1978).107-117
- 6) Kitano, M, Kawashima, M, Hayashi, K, *Experimental Studies on Decompression Sickness*. *Seikeigeka To Saigaigeka* 27(1978).653-658
- 7) Charles E., Lehner, Edward H., Lanphier, Michael A, Kawashima, M., Kitano, M., Mano, Y., and Taya, Y., Wilson:

- Dive profiles control the risk of dysbaric osteonecrosis: Validation in Japanese diving fishermen and sheep. Proceedings of the 11th meeting of the United States-Japan cooperative program in natural resources (1991).85-101
- 8) Kitano, M., Kawasihima, M., Taya, Y., Charles E., Lehner and Edward H. Lanphier, Histopathological analysis of dysbaric osteonecrosis experimentally induced in sheep. Proceedings of the 11th meeting of the United States-Japan cooperative program in natural resources (1991).36-47
 - 9) Kitano, M, Charles E., Lehner, Kawashima, M, Taya, Y and Edward H. Lanphier, Experimentally Induce Dysbaric Osteonecrosis in sheep: a Histopathological Analysis. South Pacific Study 13.2(1993).173-182)
 - 10) Kawashima, M, Hayashi, K, Torisu, T, Tamura ,H, Iwabuchi, A and Tezuka, Y, Effect of Vitamin E on Platelets Changes Associated with Decompression. Seikeigeka To Saigaijeka 29(1980).766-771
 - 11) Kuribayashi, M, Fujioka, K and Kubo, S, Prevention of Steroid induced Osteonecrosis, Idiopathic Osteonecrosis. Kubo et al. eds, Kinpoudou, Kyoto(2010). 160-163
 - 12) Ishida, M, Fujioka, K and Kubo, S, Prevention of steroid-induced Osteonecrosis Electric Stimulation in Rabbit. Idiopathic Osteonecrosis. Kubo et al. eds, Kinpoudou, Kyoto(2010).164-169
 - 13) Nishi, T, Prevention of steroid-induced Osteonecrosis Biphophonate for early stage Idiopathic Osteonecrosis. Idiopathic Osteonecrosis. Kubo et al. eds, Kinpoudou, Kyoto(2010).224-228